
 **MacNeal Hospital**
A Member of Trinity Health

Differentiating Shoulder, Upper Back and Cervical Concerns
Illinois Osteopathic Medical Society Annual Meeting 2023


Aaron Lee, DO
Program Director
Sports Medicine Fellowship
MacNeal Hospital

*We also treat the human spirit.**

 **MacNeal Hospital**

Objectives:

- At the completion of this session, participants will be able to:
 - Describe common shoulder, upper back and cervical spine issues that may be encountered in the office setting
 - Apply a systematic approach to the evaluation of patients presenting with concerns of these areas
 - Utilize a framework for treating conditions in these areas
 - Demonstrate Osteopathic Manipulative Techniques for somatic dysfunctions of the shoulder girdle, upper back and c-spine

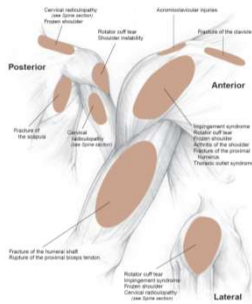
 **MacNeal Hospital**

Why does this matter to you?

- Cervical and upper back/shoulder girdle injuries often mimic each other
- There is a great deal of interplay between injuries/ concerns in these areas with reciprocal pain referral patterns
- It is common for injuries in these areas to coexist



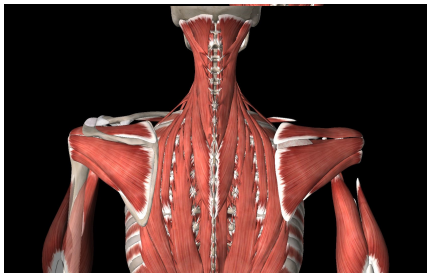
PAIN DIAGRAM
Shoulder

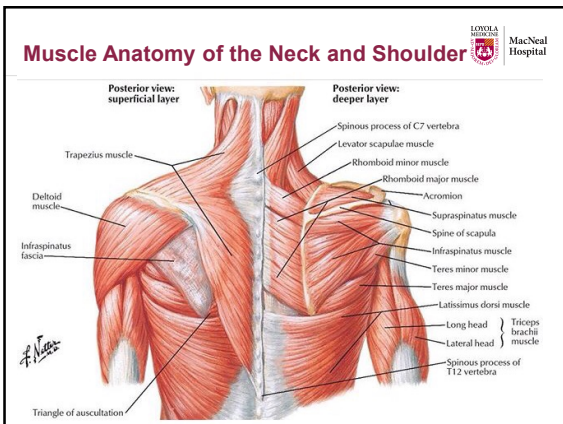


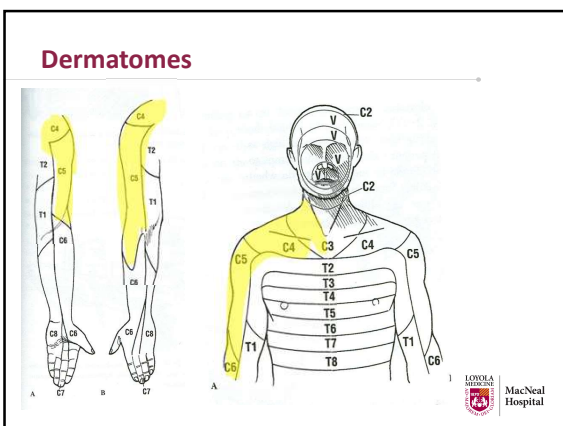
Essentials of Musculoskeletal Care, 5th Edition. 2016. AAOS.

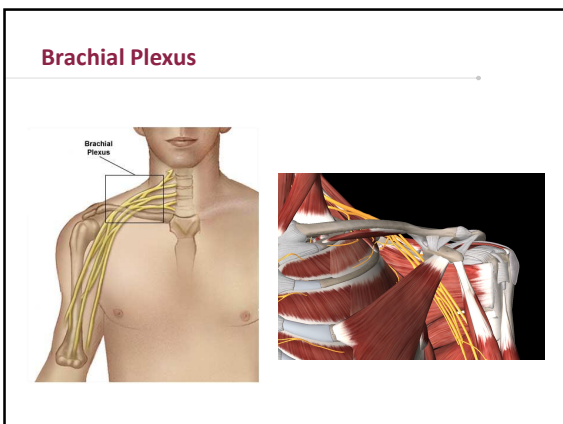


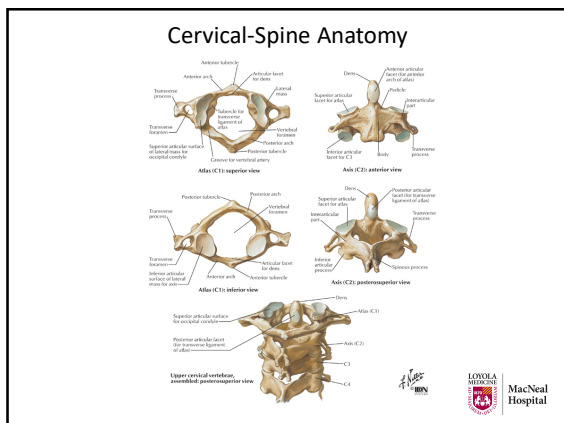
Muscle Anatomy of the Neck and Shoulder

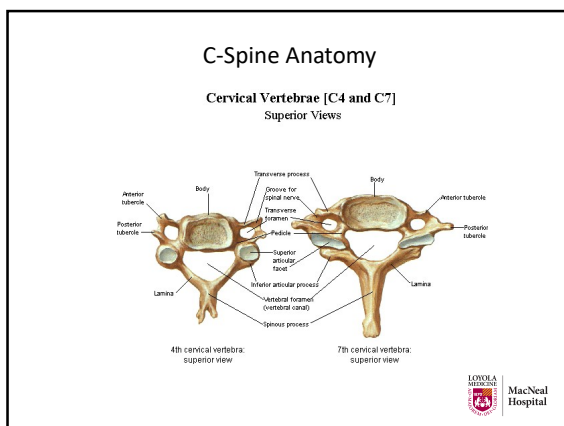












Case

- A 32 y/o woman presents for evaluation of neck pain following a car accident. She was the restrained driver of a delivery van when she was rear ended at a stop sign. The car that hit her was travelling ~ 15 mph. Her airbag did not deploy. Her pain is posterior and she notes that she cannot turn her head. She has no numbness tingling or weakness.
- What is the most likely diagnosis?

Logos for Loyola University Chicago and MacNeal Hospital are visible in the bottom right corner.


Acute Cervical Sprain/Strain

Sprain (“whiplash”): injury to the intra-spinal ligamentous unit

Strain: injury to the musculotendinous unit


Localized pain that limits ROM

Most common injury of the c-spine




Acute Cervical Sprain/Strain

- Presents with pain to the posterior neck and limited ROM
- Dull, achy or burning pain that does not radiate
- Acute injuries have “boggy” spasm
- Chronic injuries have “ropey” spasm
- Can result in tight trapezius/ upper back muscles that can lead to shoulder pain and dysfunction
- Can lead to cervicogenic headaches



Management

- Treat with activity modification/ rest
- Pain relief
 - NSAIDs or Tylenol
 - Limited or short course of muscle relaxants
- Supportive care
 - Massage, heat, TENS unit may provide relief
- Osteopathic Manipulative Therapy (OMT) may improve short term and intermediate symptoms
- For persistent symptoms, physical therapy may be indicated



Chronic Cervical Pain

- Pain that persists >12 weeks
- Treatment approach is essentially the same as acute neck pain
- Long term use of muscle relaxants and narcotics are not shown to be effective
- OMT can improve patient satisfaction, decrease pain, and improve functionality
- There is an increased role for supportive/ alternative therapies



Myofascial Upper Back Pain

- Can present acutely or chronically
- Frequently associated with overuse or poor ergonomic set up for activities
- Will often refer to either the shoulder, neck or both
- Can also lead to headaches
- Treatment approach is the same as for the cervical spine



Delivering neck pain – case redux

- A 32 y/o woman presents for evaluation of neck and arm pain following a MVA while driving a delivery van...
- Her pain is posterior and is associated with pain in her trapezius and lateral shoulder. She describes that pain as severe and “burning”. She notes that she cannot turn her head and has difficulty lifting her arm.
- What is the most likely diagnosis?



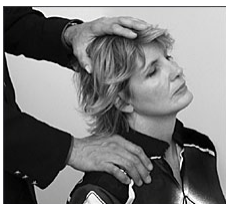Intervertebral Disc Injuries (herniation)

- Suspect with acute neurologic deficits and negative C-spine x-rays
- May or may not have neurologic deficits on exam
- Typically present with "burning" or "electric" pain in the neck that radiates to the upper shoulder or into the arm and hands
 - Up to ¼ of patients with cervical radiculopathy have cooccurring painful shoulder impingement
- May have positive Spurling's maneuver



Spurling's Maneuver

- Provoke symptoms of nerve root irritation
- Side bend, extend, rotate head Examiner presses straight down
- Positive = pain
- Positive test indicates likely c-spine radiculopathy



Cervical Radiculopathy: Treatment

- Consider short course of prednisone
- NSAIDs for pain relief
 - Consider short term use of narcotics for severe pain
- Typically resolve in 3-12 weeks
- MRI for worsening symptoms, red flags, or persistent symptoms after 4-8 weeks of no improvement
- Pain management referral may be indicated



Not so fast though...

LOVOLA MEDICINE
MacNeal Hospital

Brachial Plexus Anatomy

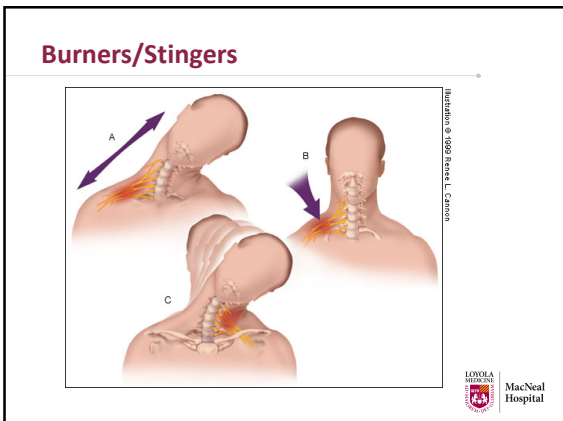
© 2006 Elsevier Inc. All rights reserved. ISBN: 978-0-7053-2345-0

LOVOLA MEDICINE
MacNeal Hospital

“Burners/ Stingers”

- Transient burning pain down the arm
 - May include numbness, paresthesias or weakness
 - May last minutes to 24 hours or more
- Due to a traction or compression injury of the brachial plexus
 - Upper Trunk (C5-C6) most commonly
- Cervical Xray if suspected neck injury
- EMG for symptoms > 3 weeks
 - EMG findings may persist for weeks or years after motor deficits resolve

LOVOLA MEDICINE
MacNeal Hospital



Burner Management

- Rest/activity modification until asymptomatic
- Exercises to increase flexibility
- NSAIDs may provide relief
- Physical therapy is appropriate for persistent symptoms

LOYOLA UNIVERSITY CHICAGO
MacNeal Hospital

Delivering neck pain – case redux

- A 32 y/o woman presents for evaluation of neck and arm pain following a MVA while driving a delivery van...
- Her pain is severe and is associated with pain in her trapezius and lateral shoulder. She notes that she cannot turn her head or lift her arm. She has noticed extensive bruising in her axilla.
- What is the most likely diagnosis?

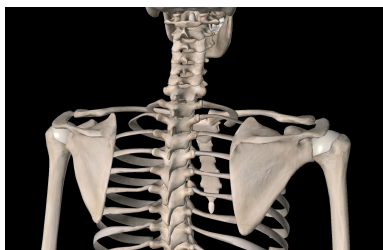LOYOLA UNIVERSITY CHICAGO
MacNeal Hospital

Differential for someone that is unable to lift their arm?

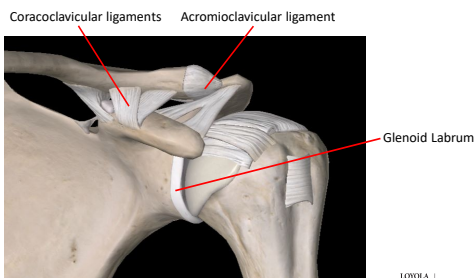
- Neural
 - Nerve injury
 - Stretch, concussion, or transection
 - Compression
 - Disc herniation
 - Acute injury
 - Fracture, etc..
 - Muscular
 - Stretch
 - Stinger
- Muscular
 - Pain
 - Injury, overuse
 - Injury
 - Full or partial thickness tear
- Mechanical
 - Dislocation
 - Labral tear, loose body

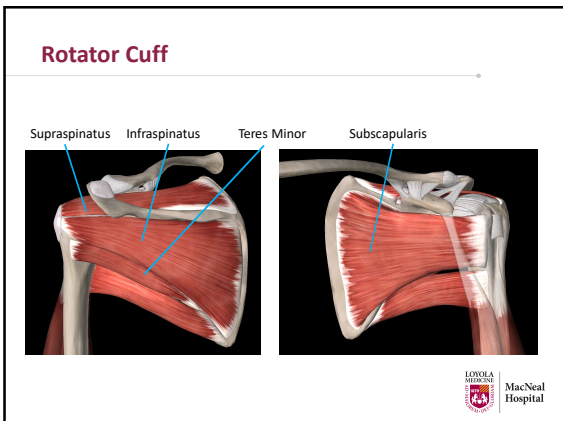


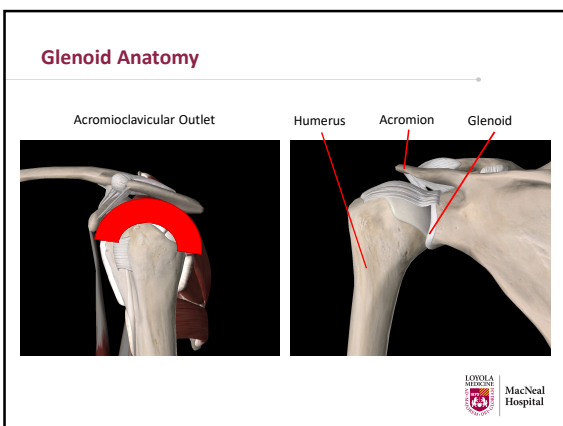
Bony Anatomy

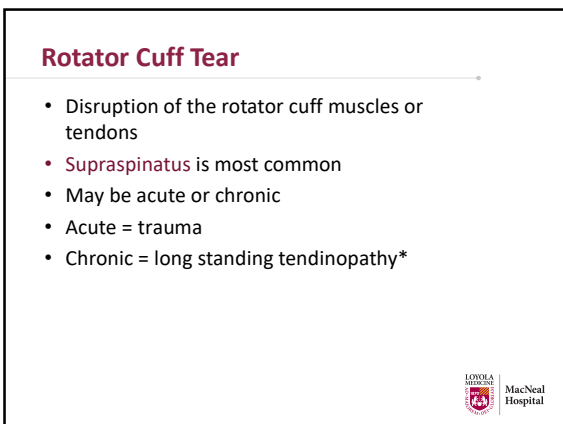


Ligamentous Anatomy







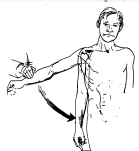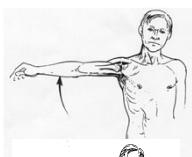

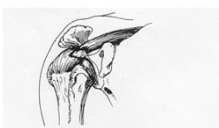
Rotator Cuff Tears

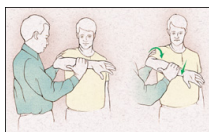
- Weakness is common, but not universal
- Pain with overhead activities
- Weakness with active muscle testing
- + Drop arm test on exam
 - For acute tears
- Chronic tears will often present with night pain along the lateral shoulder/ arm



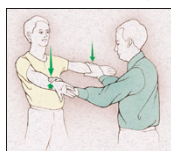
Rotator Cuff Tear: Drop Arm Test



Shoulder Examination Maneuvers

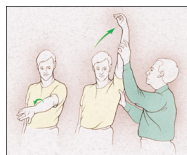


Hawkin's Maneuver



Empty Can Test

Am Fam Physician. 2000 May 15;61(10):3079-3088.



Neer Impingement Test



Rotator Cuff Tears: Evaluation

- Xray:
 - Necessary in traumatic injuries
- MRI:
 - Early imaging is recommended for acute/traumatic injuries
 - Especially in young patients
 - After failure to improve in 4-8 weeks in chronic injuries/pain



Rotator Cuff Tears: Treatment

- Acute full thickness tears should be referred for surgical repair
 - Especially in young patients
- Chronic shoulder injuries should have a trial of physical therapy (PT) prior to surgery
- Injuries > 1 year old are less likely to be treated successfully with PT



Rotator Cuff Strain

- Partial thickness or stretch injuries
- May present with a less traumatic mechanism
- Exam will be less impressive
- Can progress to tendinopathy
 - “Rotator cuff syndrome”
 - “Rotator cuff impingement”




Rotator Cuff Syndrome

Treat conservatively


- NSAIDs/Tylenol
- Activity modification
- Rehabilitation
- Role for OMT for compensatory muscle spasm/ dysfunction

Hold off on imaging unless failing management




Delivering neck pain – redux... reduced

- A 32 y/o woman presents for evaluation of neck and arm pain following a MVA while driving a delivery van that occurred 6 weeks ago...
- Her pain is primarily in the lateral shoulder and is associated with pain in her trapezius and neck and has been worsening in the last 2 weeks. She describes the pain as severe. She notes that she has been developing difficulty reaching up and putting on her shirt .
- What is the most likely diagnosis?



Frozen Shoulder

- “Adhesive Capsulitis”
- Idiopathic pain
- Loss of active and passive ROM
- Soft tissue contraction of the capsule
- Night pain is common
- Can occur after trauma or rotator cuff pathology



Frozen Shoulder

4 Stages

Pain Freezing Frozen Thawing

May be self limited 1-2 years




Frozen Shoulder: Epidemiology

- More common in women
- Typically between Ages of 40-60
- ***More common in patients with diabetes***
 - Also thyroid dz, cervical disc disease
- ****Shoulder pain in a patient with diabetes is frozen shoulder until proven otherwise****

Frozen Shoulder: Treatment

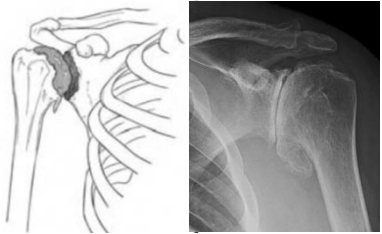
- Conservative treatment
 - Rehabilitation focusing on ROM
 - Pain control
 - NSAID course or acetaminophen
 - Corticosteroid injection
- Surgical intervention
 - Consider if failed conservative management for 3-6 mos
 - Manipulation under anesthesia
 - Capsular release

Glenohumeral Arthritis

-  Similar presentation as frozen shoulder. Can be aggravated by trauma.
-  More common in older age groups.
-  Progressive loss of cartilage, with associated osteophyte formation and loss of joint space. Changes present on xray. Frozen shoulder has normal xray.




LOYOLA MEDICINE MacNeal Hospital

Glenohumeral Arthritis



LOYOLA MEDICINE MacNeal Hospital

Glenohumeral Arthritis

-  **Treat similar to frozen shoulder:**
Course of NSAIDs/
acetaminophen
Corticosteroid injection
-  **Gentle ROM exercises**
-  **Refer to Orthopedic surgery if:**
Worsening motion
Falls conservative mgt for 3-6 mos

LOYOLA MEDICINE MacNeal Hospital

So where does that leave us?




LOYOLA MEDICINE
MacNeal Hospital

Some thoughts:

- Cervical and shoulder injuries can have similar mechanisms of injury
- These injuries can lead to compensatory issues that mimic symptoms in the other area
- It may not be “either, or”, but can be “and”
- There are some differentiating features that help with your diagnosis

LOYOLA MEDICINE
MacNeal Hospital

Acute symptoms following trauma:





- Most likely diagnoses
 - Cervical strain
 - Rotator cuff injury
 - Cervical disc herniation
 - Stinger/ Burner

LOYOLA MEDICINE
MacNeal Hospital



“Burning, stinging, electric” symptoms:

- Most likely diagnoses
 - Cervical disc herniations
 - Stinger/ burners
 - Brachial plexopathy
 - *myofascial trigger points can present as "burning" pain that radiates for some patients





Chronic symptoms:

- Most likely diagnoses
 - Post traumatic rotator cuff tendinopathy
 - Frozen shoulder
 - Flare-up of glenohumeral arthritis



Severe pain present:

- Most likely diagnoses
 - Traumatic
 - Cervical radiculopathy
 - Rotator cuff injury
 - Atraumatic
 - Adhesive capsulitis



When your source is cervical:

- Associated trapezius spasm, or radiculopathy may lead to shoulder/ upper extremity pain
- But... the shoulder exam will typically be normal



When your source is the shoulder:

- Compensatory use of the upper back and trapezius musculature can lead to cervical symptoms
- But... the shoulder exam will be abnormal
- The shoulder exam is very good at indicating there is an issue, but not always good at identifying the specific issue



In summary

- Cervical and shoulder injuries can be difficult to differentiate
- Your history and physical exam should guide your decision making
 - Especially the shoulder exam
- It may not be “either, or”, but “and”
- Relative rest, supportive care, pain control, and rehabilitation are typically your treatment for these areas



Summary Continued

- In my experience, there is an extremely relevant role for OMT for treating patients with concerns of the cervical spine, upper back and shoulder girdle




Questions?



References


1. *Am Fam Physician*. 2000 May 15;61(10):3079-3088.
2. *Am Fam Physician*. 2000 Jun 1;61(11):3291-3300.
3. *Am Fam Physician*. 2008;77(4):453-460.
4. *Am Fam Physician*. 2008 Feb 15;77(4):493-497.
5. *Am Fam Physician*. 2019;99(4):248-252
6. *Am Fam Physician*. 2020;102(3):150-156
7. *The American Journal of Medicine*. 2016 Sep;129 (9):913-918.
8. *Br J Sports Med*. 2008;42:80-92.
9. *Cochrane Database Syst Rev*. 2015 Sep 23;(9):CD004249.
10. *Essentials of Musculoskeletal Care*, 5- Edition. 2016. AAOS.
11. *Global Spine Journal*. 2020 April; 10 (2): 195-208.



 **Selected OMT Techniques for the Cervical, Upper Back and Shoulder Girdle**
Aaron Lee DO
A Member of Trinity Health


Approach

- I find that my overall approach is similar whether treating acute or chronic patients
- When encountering concerns in these areas, I typically treat all three zones regardless of the primary lesion
- Soft tissue techniques, myofascial release and mobilization are my primary treatments of choice
 - Counterstrain can be very effective as well




Cervical Soft Tissue/ Mobilization

- Can perform standing alongside the patient or seated at the head of the table
- Work up and down the c-spine
- Transition to mobilization by actively "motion-testing" along the posterior articular pillars





Cervical Soft Tissue/ Mobilization

12 The therapist stands to the right




12 The therapist stands to the left






Suboccipital Release

12 The therapist stands to the right




- Patient is supine
- Support the occiput and place the finger pads just distal to the occipital ridge



Cervical Muscle Energy

- Treat flexion, side-bending and rotation
- Thoughtful position of your arms can facilitate this



Cervical Muscle Energy

LOYOLA UNIVERSITY
MacNeal Hospital

Cervical Muscle Energy

--	--

LOYOLA UNIVERSITY
MacNeal Hospital

Personal Preferred First Rib Technique

	<ul style="list-style-type: none">• Mobilization technique<ul style="list-style-type: none">– Exaggerate the dysfunction and correct during exhalation– Typically RrSr– Mobilize the operculum with your palm
--	---


LOYOLA UNIVERSITY
MacNeal Hospital

Trapezius Pinch

- Patient remains supine
- Compress the muscle body of the trapezius between the thumb and first finger
- Can transition to a release procedure by forming a "v" with your hands and applying lateral traction along the thoracic or trapezius musculature



Trapezius Pinch



Thoracic Soft Tissue

- Can be performed prone or in lateral Sims
- In prone position consider crossed transitioning to pisiform positioning
- In lateral Sims position you can use counter force along the anterior shoulder girdle to increase your depth



Thoracic Soft Tissue

LOYOLA UNIVERSITY
MacNeal Hospital

Shoulder Mobilization

- My personal staged approach
 - Myofascial ROM of the shoulder girdle
 - Encourage abduction of the scapula
 - Transition to scapular distraction

LOYOLA UNIVERSITY
MacNeal Hospital

Shoulder Mobilization

--	--

LOYOLA UNIVERSITY
MacNeal Hospital
